

AIUM–ACR–SPR–SRU Practice Parameter for the Performance of an Ultrasound Examination for Detection and Assessment of Developmental Dysplasia of the Hip

Preamble

The American Institute of Ultrasound in Medicine (AIUM) is a multidisciplinary association dedicated to advancing the safe and effective use of ultrasound in medicine through professional and public education, research, development of parameters, and accreditation.

The AIUM represents the entire range of clinical and basic science interests in medical diagnostic ultrasound, and, with hundreds of volunteers, the AIUM has promoted the safe and effective use of ultrasound in clinical medicine since 1952. This document and others like it will continue to advance this mission.

Practice parameters of the AIUM are intended to provide the medical ultrasound community with parameters for the performance and recording of high-quality ultrasound examinations. The parameters reflect what the AIUM considers the minimum criteria for a complete examination in each area but are not intended to establish a legal standard of care. AIUM-accredited practices are expected to generally follow the parameters with recognition that deviations from these parameters will be needed in some cases, depending on patient needs and available equipment. Practices are encouraged to go beyond the parameters to provide additional service and information as needed.

Introduction

The clinical aspects contained in specific sections of this practice parameter (Introduction, Indications/Contraindications and Timing, Specifications of the Examination, and Equipment Specifications) were revised collaboratively by the AIUM, the American College of Radiology (ACR), the Society for Pediatric Radiology (SPR), and the Society of Radiologists in Ultrasound (SRU). Recommendations for Qualifications and Responsibilities of Personnel; Written Request for the Examination; Documentation; and

doi:10.1002/jum.14829

Quality Control and Improvement, Safety, Infection Control, and Patient Education vary among the organizations and are addressed by each separately.

This practice parameter is intended to assist practitioners performing ultrasound studies for detection and assessment of developmental dysplasia of the hip (DDH). Adherence to the following recommendations will maximize the probability of detecting most of the abnormalities that relate to acetabular morphology, position of the femoral head, and stability.

When available, ultrasound imaging is the preferred method for diagnostic imaging of the immature hip.^{1,2} It affords direct visualization of the cartilaginous and other components of the hip joint and permits a dynamic examination that can be used to assess hip stability. The value of ultrasound diminishes as the femoral head ossifies; therefore, radiography is preferable for patients 6 months of age or older, unless the relationship of the femoral head to the acetabulum (including the triradiate cartilage) is adequately visualized with ultrasound.

Indications/Contraindications and Timing

Two of the strongest risk factors for DDH are a female neonate in a frank breech presentation at birth and a history of a parent and/or a sibling with DDH.³

Accepted indications for ultrasound of the infant hip include but are not limited to:

1. Abnormal or equivocal findings of hip instability on physical examination of the hip;
2. Any family history of DDH;
3. Breech presentation at birth;
4. Neuromuscular conditions; and
5. Monitoring infants with DDH undergoing treatment.

Relative indications for ultrasound of the infant hip include but are not limited to:

1. Oligohydramnios; and
2. Other intrauterine causes of postural molding.

There are no absolute contraindications to ultrasound of the infant hip for DDH, but as discussed above, the study becomes less reliable compared to radiography as ossification of the femoral head progresses. Because of the presence of physiologic laxity,

hip ultrasound examinations are usually not performed on patients younger than 6 weeks of age unless indicated on the basis of an abnormal finding on physical examination.⁴

Qualifications and Responsibilities of Personnel

See www.aium.org for AIUM Official Statements, including *Standards and Guidelines for the Accreditation of Ultrasound Practices* and relevant Physician Training Guidelines.⁵

Written Request for the Examination

The written or electronic request for an ultrasound examination should provide sufficient information to allow for the appropriate performance and interpretation of the examination. The request for the examination must be originated by a physician or another appropriately licensed health care provider or under the physician's or provider's direction. The accompanying clinical information should be provided by a physician or other appropriate health care provider familiar with the patient's clinical situation and should be consistent with relevant legal and local health care facility requirements.

Specifications of the Examination^{6,7}

Both hips should be examined. The diagnostic examination for DDH incorporates 2 orthogonal planes: a coronal view in the standard plane at rest and a transverse view of the flexed hip with and without stress. This enables an assessment of hip position, stability, and acetabular morphology.

If position, stability, and/or morphology cannot be assessed when attempting to perform a complete examination, the report should note the portion not performed. It is acceptable to perform the examination with the infant in a supine or in each lateral decubitus position separately.

Morphology is assessed at rest. The stress maneuver (posterior push maneuver) is performed to evaluate for hip instability with the hip and knee

flexed and the thigh adducted (Barlow maneuver). If the femoral head is subluxated, subluxable, dislocated, or dislocatable, reducibility can be assessed by abducting and externally rotating the hip (Ortolani maneuver). If the examiner chooses, additional views and maneuvers can be obtained. It is important that the infant be relaxed when hips are assessed for instability. Feeding the infant during the examination can increase comfort and cooperation.⁸ Stress maneuvers are not performed when the patient is immobilized in a Pavlik harness or splint unless specifically requested by the referring orthopedic surgeon.⁹

Coronal View

The anatomic coronal plane is approximately parallel to the infant’s body. If the superior edge of the transducer is rotated 10° to 15° (usually posteriorly) into an oblique coronal plane, the ilium will appear straight. After adjustment to ensure that the imaging plane extends through the deepest part of the acetabulum (including visualization of the triradiate cartilage and the ischium), the resulting image will be a coronal view in the standard plane.

The standard plane is defined by identifying a straight iliac line, the tip of the acetabular labrum, and the transition from the os ilium to the triradiate cartilage (Figure 1). The coronal view in the standard plane can be obtained with the hip in the physiologic neutral position (15°–20° flexion) or in the flexed position. The femoral head position and displacement are noted.

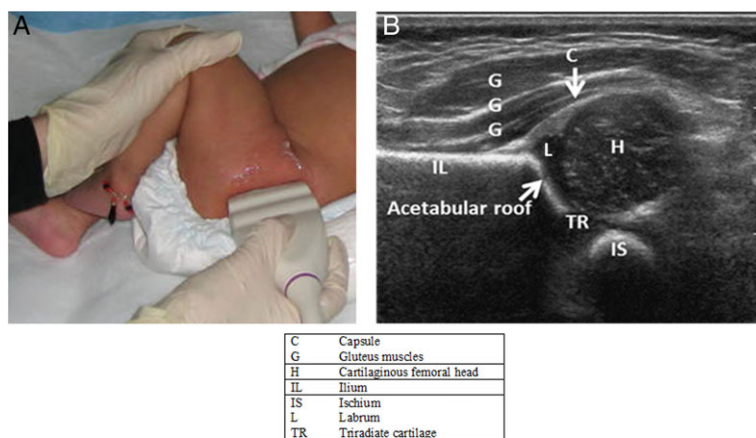
Acetabular morphology is assessed in the coronal neutral view and may be validated by measuring the acetabular alpha angle (normally ≥60°). Validation by angle and femoral head coverage measurement is optional. Performance of stress in this plane is also optional.

The examination is performed with the hip flexed at 90°. The transverse plane is the anatomic transverse or axial plane with respect to the body, similar to the plane of an axial computed tomographic image (Figure 2). With the transducer nearly parallel to the femoral shaft, the femoral shaft is seen anteriorly, terminating in the femoral head, which rests on the ischium. The hip is tested for position at rest with passive abduction and adduction. The transducer is kept parallel to the femoral shaft placed in a posterolateral position so that imaging can be accomplished while the hip is abducted and adducted (Ortolani and Barlow maneuvers). Next, gentle stress is applied to assess stability. If the relationship of the femoral head with the posterior acetabulum changes with gentle stress, the hip is unstable. Again, application of stress is omitted when hips are being examined in a Pavlik harness or splint device unless otherwise requested by the orthopedic surgeon.

Modification of the Diagnostic Examination

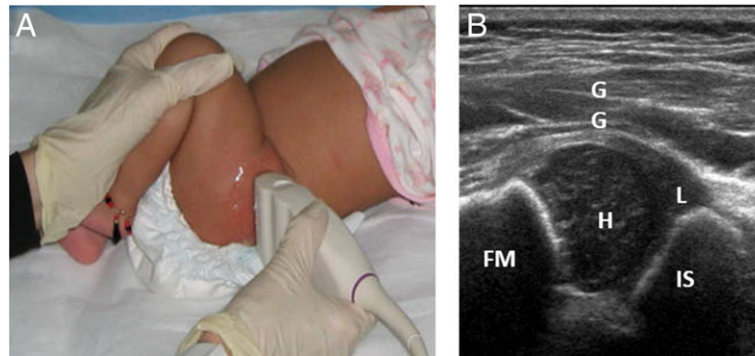
The supervising physician may modify the examination depending on clinical circumstances, such as during or after treatment for DDH.

Figure 1. A, Coronal view: the ultrasound transducer is placed parallel to the lateral aspect of the infant’s hip.



••••

Figure 2. A, Transverse flexion view: the hip and knee are flexed 90°, and the ultrasound transducer is placed perpendicular to the lateral aspect of the infant's hip nearly parallel to the femoral shaft. **B**, Transverse ultrasound image.



G	Gluteus muscles
H	Cartilaginous femoral head
L	Labrum
IS	Ischium
FM	Femoral metaphysis

Documentation

Adequate documentation is essential for high-quality patient care. There should be a permanent record of the ultrasound examination and its interpretation. A comparison with prior relevant imaging studies may prove helpful. Images of all appropriate areas, both normal and abnormal, should be recorded. Variations from normal size should generally be accompanied by measurements. Images should include the patient identification, facility identification, examination date, hip being imaged, image orientation, and whether stress is being applied. An official interpretation (final report) of the ultrasound examination should be included in the patient's medical record, indicating acetabular morphology, the position of the femoral head, and stability.⁹

Retention of the ultrasound images should be consistent both with clinical needs and with relevant legal and local health care facility requirements.

Reporting should be in accordance with the *AIUM Practice Parameter for Documentation of an Ultrasound Examination*.¹⁰

Equipment Specifications

A hip ultrasound examination for detecting DDH should be performed with a high-frequency linear

transducer that permits penetration of the soft tissues. Total ultrasound exposure should be kept as low as reasonably achievable (ALARA) while optimizing diagnostic information.

Quality Control and Improvement, Safety, Infection Control, and Patient Education

Policies and procedures related to quality control, patient education, infection control, and safety should be developed and implemented in accordance with the *AIUM Standards and Guidelines for the Accreditation of Ultrasound Practices*.

Equipment performance monitoring should be in accordance with the *AIUM Standards and Guidelines for the Accreditation of Ultrasound Practices*.

ALARA Principle

The potential benefits and risks of each examination should be considered. The ALARA principle should be observed by adjusting controls that affect the acoustic output and by considering transducer dwell times. Further details on ALARA may be found in the AIUM publication *Medical Ultrasound Safety*, Third Edition.¹¹

Acknowledgments

This parameter was revised by the AIUM in collaboration with the ACR, the SPR, and the SRU according to the process described in the AIUM Clinical Standards Committee Manual.

Collaborative Committee

Members represent their societies in the initial version and final revision of this practice parameter.

ACR	AIUM
Terry L. Levin, MD, chair Maria A. Calvo-Garcia, MD Monica S. Epelman, MD Henrietta K. Rosenberg, MD	Brian D. Coley, MD T. Robin Goodman, MBBS Harriet J. Paltiel, MD
SPR	SRU
Richard D. Bellah, MD Christian L. Carlson, MD Rachelle Goldfisher, MD Jonathan R. Wood, MD	Lynn A. Fordham, MD Valerie L. Ward, MD

AIUM Clinical Standards Committee

John Pellerito, MD, chair
Bryann Bromley, MD, vice chair
Sandra Allison, MD
Anil Chauhan, MD
Stamatia Destounis, MD
Eitan Dickman, MD, RDMS
Beth Kline-Fath, MD
Joan Mastrobattista, MD
Marsha Neumyer, BS, RVT
Tatjana Rundek, MD, PhD
Khaled Sakhel, MD
James Shwayder, MD, JD
Ants Toi, MD
Joseph Wax, MD

Isabelle Wilkins, MD

Original copyright 2003; revised 2018, 2013, 2008
Renamed 2015

References

1. Roposch A, Wright JG. Increased diagnostic information and understanding disease: uncertainty in the diagnosis of developmental hip dysplasia. *Radiology* 2007; 242:355–359.
2. Smergel E, Losik SB, Rosenberg HK. Sonography of hip dysplasia. *Ultrasound Q* 2004; 20:201–216.
3. Bache CE, Clegg J, Herron M. Risk factors for developmental dysplasia of the hip: ultrasonographic findings in the neonatal period. *J Pediatr Orthop B* 2002; 11:212–218.
4. Mulpuri K, Song KM, Gross RH, et al. The American Academy of Orthopaedic Surgeons evidence-based guideline on detection and nonoperative management of pediatric developmental dysplasia of the hip in infants up to six months of age. *J Bone Joint Surg Am* 2015; 97: 1717–1718.
5. American Institute of Ultrasound in Medicine. *AIUM physician training guidelines*. American Institute of Ultrasound in Medicine website. <https://www.aium.org/resources/ptGuidelines.aspx>. Accessed June 8, 2018.
6. Harcke HT, Grissom LE. Performing dynamic sonography of the infant hip. *AJR Am J Roentgenol* 1990; 155:837–844.
7. Morin C, Harcke HT, MacEwen GD. The infant hip: real-time US assessment of acetabular development. *Radiology* 1985; 157: 673–677.
8. Grissom LE, Harcke HT, Kumar SJ, Bassett GS, MacEwen GD. Ultrasound evaluation of hip position in the Pavlik harness. *J Ultrasound Med* 1988; 7:1–6.
9. Roposch A, Moreau NM, Uleryk E, Doria AS. Developmental dysplasia of the hip: quality of reporting of diagnostic accuracy for US. *Radiology* 2006; 241:854–860.
10. American Institute of Ultrasound in Medicine. AIUM practice parameter for documentation of an ultrasound examination. American Institute of Ultrasound in Medicine website. <http://www.aium.org/resources/guidelines/documentation.pdf>. Accessed June 10, 2018.
11. American Institute of Ultrasound in Medicine. *Medical Ultrasound Safety*. 3rd ed. Laurel, MD: American Institute of Ultrasound in Medicine; 2014.